


RESEARCH

Open Access



Ligation versus stapling in video-assisted thoracoscopic (VATS) bullectomy; early outcome of a low cost technique

Mohamed Osman Omar Hassan^{1*} , Linyou Zhang², Mahmoud Khairy El-Haish³,
Mohsen Saber Mohamed Ahmed⁴ and Hussein Elkhaty³

Abstract

Background Spontaneous pneumothorax is thoracic condition, with annual incidence of 7 to 9 cases per 100,000 people. Most of thoracic surgeons prefer minimally invasive method that uses staplers to resect bullous parenchyma, but this technique is costly. Now, the problem of rising health care costs is faced by all countries all over the world. As result, preventing use of disposable consumables in video-assisted thoracic surgery (VATS) will aid in cost control. In our study, we described a new cheap technique which was VATS ligation of bullae by silk ligature and we compared it to standard technique of using staplers in VATS bullectomy.

Aim of Work We aimed to investigate the results of VATS ligation of bullae by silk ligature in comparison to using staplers in VATS bullectomy.

Patient & techniques This was retrospective research done on 120 studied cases at cardiothoracic surgery, 2nd Affiliated Hospital, Harbin Medical University, China and Assiut University Hospital, Egypt from March 2020 to December 2021.

Results We retrospectively investigate data of 120 patients and there was no variation in patient characteristics among VATS bullectomy using staplers and VATS bullae ligation. Air leak duration and post-operative drainage were statistically significant higher in VATS bullectomy using staplers than bullae ligation.

Hospital stay duration (mean = 3.800 ± 1.070 vs 4.917 ± 2.794) and complications were statistically significant higher in VATS bullectomy using staplers than thoracoscopic bullae ligation.

Conclusion Treatment of spontaneous pneumothorax by thoracoscopic ligation of bullae by silk ligature is comparable to VATS bullectomy using staplers in short-term results and offers less complications and better economic results.

Keywords Ligation, Stapling, Video-assisted thoracoscopic (VATS), Bullectomy

*Correspondence:

Mohamed Osman Omar Hassan

Mohamed.osman@med.svu.edu.eg

Full list of author information is available at the end of the article



© The Author(s) 2023. **Open Access** This article is licensed under a Creative Commons Attribution 4.0 International License, which permits use, sharing, adaptation, distribution and reproduction in any medium or format, as long as you give appropriate credit to the original author(s) and the source, provide a link to the Creative Commons licence, and indicate if changes were made. The images or other third party material in this article are included in the article's Creative Commons licence, unless indicated otherwise in a credit line to the material. If material is not included in the article's Creative Commons licence and your intended use is not permitted by statutory regulation or exceeds the permitted use, you will need to obtain permission directly from the copyright holder. To view a copy of this licence, visit <http://creativecommons.org/licenses/by/4.0/>.

Background

Spontaneous pneumothorax is thoracic condition with annual incidence of 7 to 9 cases per 100,000 people [1]. After first episode, recurrence rate is estimated to be twenty three: fifty percent, with possible increase to eighty percent after 3rd pneumothorax [2]. Because of the advantages of video-assisted thoracoscopic surgery—VATS is regarded gold standard surgical method for therapy of pneumothorax to resect blebs or bullae and achieve satisfactory pleurodesis due to reduced postoperative pain, shorter duration of chest tube insertion, & consequently shorter hospital stay [3].

Numerous methods, such as stapler, laser ablation, and endoscopic loop ligation, have been characterized [3]. Most of thoracic surgeons prefer minimally invasive method that uses staplers to remove bullous parenchyma, however this method is costly [4].

Cost-effectiveness is an important issue nowadays [5]. Even though endoscopic surgery has several advantages, requirement for more expensive endoscopic consumables is frequently associated with high costs. As result, preventing use of disposable consumables in video-assisted thoracic surgery will aid in cost control [6].

In our study, we described a new cheap technique which was thoracoscopic ligation of bullae by silk ligature and we compared this technique with using staplers in VATS bullectomy.

Methods

Aim of study

We aimed to investigate the results of VATS ligation of bullae by silk ligature in comparison to using staplers in VATS bullectomy.

Patients and techniques

This was retrospective research done at cardiothoracic surgery, 2nd Affiliated Hospital, Harbin Medical University, China and Assiut University Hospital, Egypt from March 2020 to December 2021.

Research contained total of 120 studied cases undergoing VATS bullectomy & pleurodesis and divided according to procedure done into 2 equal groups **Group A:** -studied cases underwent VATS bullae ligation by silk suture. **Group B:**—patients underwent VATS bullectomy using stapler.

No use of low-grade suction in both groups.

Inclusion criteria

All Patients with small bullae undergoing VATS bullectomy by using staplers or VATS bullae ligation and pleurodesis. No age limitation.

Exclusion criteria

Patients with abnormal coagulation profile or taking anti-coagulants in the preoperative period and patients with

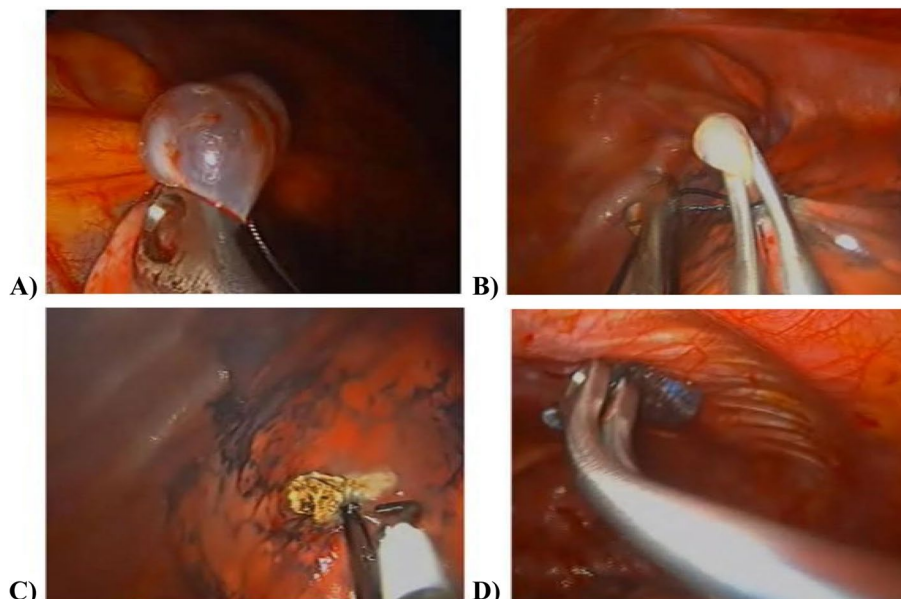


Fig. 1 VATS bulla ligation technique:- **A** Grasping bulla by lung grasping forceps. **B** Advancing a silk suture (size 1) below the clamp and ligate the silk suture by knot Pusher. Another silk suture can be ligated below the first for confirmation. **C** Cauterize the bulla by hook diathermy. **D** Apical pleural abrasion for pleurodesis via diathermy scratch pad over a long clamp

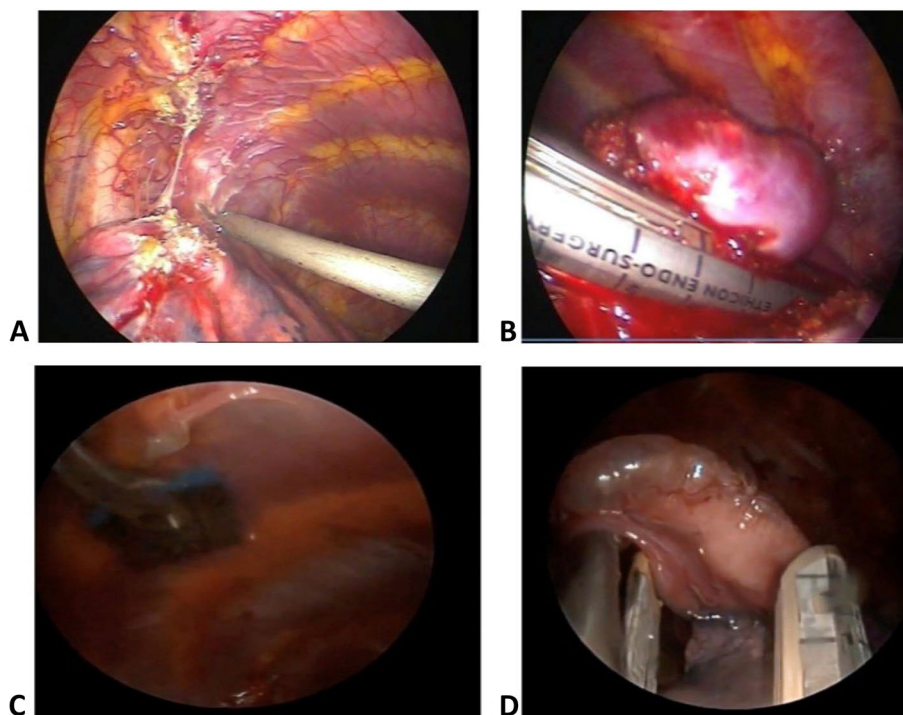


Fig. 2 VATS bullectomy by stapler technique:- **A** Breaking the adhesion and freeing of lung from chest wall. **B** Grasping bulla by lung grasping forceps and putting the stapler below the bulla. **C** Firing the stapler and exploring the stapler line for air leak and bleeding. **D** Apical pleural abrasion for pleurodesis via diathermy scratch pad over a long clamp. Some patients (26.7%) were done by pleurectomy

large bulla occupying most of the lobe who needed anatomical lobectomy Figs. 1 and 2.

Study tools

All studied cases were submitted to following

Preoperative Data Full history taking, clinical test, laboratory investigations (e.g.:—complete blood picture (CBC), prothrombin time, liver function test (LFTs) and renal function test (RFTs), radiological examination (CT chest).

The following parameters were assessed

Intraoperative

The operative time, bleeding during surgery, location of bulla, and technique of surgery (Ligation or stapling) and type of pleurodesis (pleurectomy or pleural abrasion).

Postoperative

Post-operative chest tube drainage, post-operative air leak duration and hospital stay duration.

Follow up of patients for 6 months for recurrence at the same side (Follow up performed by phone contact with patients and/or family members).

Ethical Approval

Research was accepted by Ethics Board of South Valley university (Code:—SVU-MED-CTS012-2-20-2-28).

Statistical analysis design

Collected data was reviewed, & coding was done manually. These numerical codes were fed into computer, which performed statistical analysis using Statistic Package for Social Science Version twenty two for Windows.

Results

We investigated patient's records of 120 patients in our study (94 male patients and 26 female patients) and divided into two equal groups (ligation and stapling) with mean age 29.7 in ligation group and 32.9 in stapling group.

Positive history of smoking was found in 89 patients while 31 patients were never smoker.

Dyspnea was the main complain (45 patients), followed by chest pain (44 patients) or both (31 patients). Patient were diagnosed as primary (52 patients) and secondary (68 patients) spontaneous pneumothorax.

Pneumothorax was in the right side (63 patients), in the left side (37 patients) or bilateral (20 patients) as shown in Table 1.

Table 1 Comparison of the patient characteristics and clinical data between VATS bullectomy using staplers and VATS bullae ligation

		Ligation No. = 60	Staplers No. = 60	t/x ²	P-value	Sig
Age (years)	Range	14 – 54	15 – 65	-1.619•	0.108	NS
	Mean ± SD	29.700 ± 10.582	32.900 ± 11.060			
	Median [IQR]	27 [17.50]	31.5 [17.25]			
Sex	Male	44 (73.3%)	50 (83.3%)	1.768*	0.184	NS
	Female	16 (26.7%)	10 (16.7%)			
Smoking	No	17 (28.3%)	14 (23.3%)	0.391*	0.532	NS
	Yes	43 (71.7%)	46 (76.7%)			
Complaint	Dyspnea	20 (33.3%)	25 (41.7%)	0.937•	0.626	NS
	Chest pain	23 (38.3%)	21 (35%)			
	Both	17 (28.3%)	14 (23.3%)			
Diagnosis	1ry spontaneous. Pneumothorax	24 (40%)	28 (46.7%)	0.543*	0.461	NS
	2ry spontaneous pneumothorax	36 (60%)	32 (53.3%)			
Side of pneumothorax	Right	31 (51.7%)	32 (53.3%)	2.492*	0.288	NS
	Left	16 (26.7%)	21 (35%)			
	Bilateral	13 (21.7%)	7 (11.7%)			
Number of bullae	1	36 (60%)	30 (50%)	5.497*	0.139	NS
	2	15 (25%)	26 (43.3%)			
	3	6 (10%)	3 (5%)			
	4	3 (5%)	1 (1.7%)			

P-value > 0.05: Non-significant, P-value < 0.05: Significant, P-value < 0.01: highly significant

*: Chi-square test, • independent student t test

There is no statistically significant difference in patient characteristics and clinical data between VATS bullectomy using staplers and VATS bullae ligation.

Operation duration and intra-operative bleeding are statistically significant higher in VATS bullectomy using staplers than VATS bullae ligation with a mean of 41.000 ± 8.772 min in ligation group compared to 92.383 ± 39.173 min in stapler group and 26.500 ± 12.048 ml. intraoperative bleeding in

ligation group compared to 80.083 ± 31.075 ml. in stapler group.

VATS wedge resection was performed in 56.7% of patients who were operated by stapler in comparison to none of patients operated by ligation. Pleurectomy was done in 26.7% of patients who were operated by staplers in comparison to none of patients operated by ligation as shown in Table 2.

Air leak duration and post-operative drainage are statistically significant higher in stapler group

Table 2 Comparing of operative details between VATS bullae ligation and VATS bullectomy using staplers

		Ligation No. = 60	Staplers No. = 60	t/ x 2	P-value	Sig
Type of operation	VATS wedge resection	0 (0%)	34 (56.7%)	47.442	<0.0001	HS
	VATS bullectomy	60 (100%)	26 (43.3%)			
Type of Pleurodesis	Pleural abrasion	60 (100%)	44 (73.3%)	18.642	<0.0001	HS
	Pleurectomy	0 (0%)	16 (26.7%)			
Operation duration (min)	Range	30 – 60	30 – 180	-8.437•	<0.0001	HS
	Mean ± SD	41.000 ± 8.772	92.383 ± 39.173			
	Median [IQR]	40 [20]	90 [60]			
Intra-operative bleeding (ml)	Range	10 – 50	40 – 150	-8.893•	<0.0001	HS
	Mean ± SD	26.500 ± 12.048	80.083 ± 31.075			
	Median [IQR]	20 [10]	75 [50]			

P-value > 0.05: Non-significant; P-value < 0.05: Significant; P-value < 0.01: highly significant

*: Chi-square test, • Mann Whitney test

Table 3 Comparison of the post-operative details between VATS bullae ligation and VATS bullectomy using staplers

		Ligation No. = 60	Staplers No. = 60	T	P-value	Sig
Air leak duration (day)	Range	1 – 3	1—15	-2.890•	0.004	HS
	Mean ± SD	1.700 ± 0.808	2.700 ± 2.234			
	Median [IQR]	1 [1]	2 [2]			
post-operative drainage (ml)	Range	10 – 200	25—700	-6.227•	< 0.0001	HS
	Mean ± SD	73.167 ± 49.753	225.667 ± 159.316			
	Median [IQR]	50 [75]	200 [243.75]			
Hospital stay duration (day)	Range	2 – 6	2 – 19	-2.033•	0.042	S
	Mean ± SD	3.800 ± 1.070	4.917 ± 2.794			
	Median [IQR]	4 [2]	4 [3]			
Cost of stay (L.E)	Range	350 – 1400	700 – 6800	-5.19•	< 0.001	HS
	Mean ± SD	962.5 ± 326.2	1688.33 ± 980.8			
	Median [IQR]	1050 [700]	1400 [1050]			
Total Cost (L.E)	Range	3900 – 4950	10,200 – 18,300	-9.493•	< 0.001	HS
	Mean ± SD	4498.17 ± 338.4	12,106.5 ± 1572.5			
	Median [IQR]	4550 [700]	11,950 [1840]			

P-value > 0.05: Non-significant, P-value < 0.05: Significant, P-value < 0.01: highly significant

• Mann Whitney exam

than ligation group with a mean air leak duration of 1.700 ± 0.808 days in ligation group while it was 2.700 ± 2.234 days in stapler group. Hospital stay duration is statistically significant higher in VATS bullectomy using staplers (4.917 ± 2.794 days) than ligation group (3.800 ± 1.070 days) as shown in Table 3.

No patient was complicated with post-operative infection in both groups.

The cost and postoperative air leak duration have statistically significant positive correlation with operative bleeding, operative air leakage, and hospital stay duration, as shown in Figs. 3, 4.

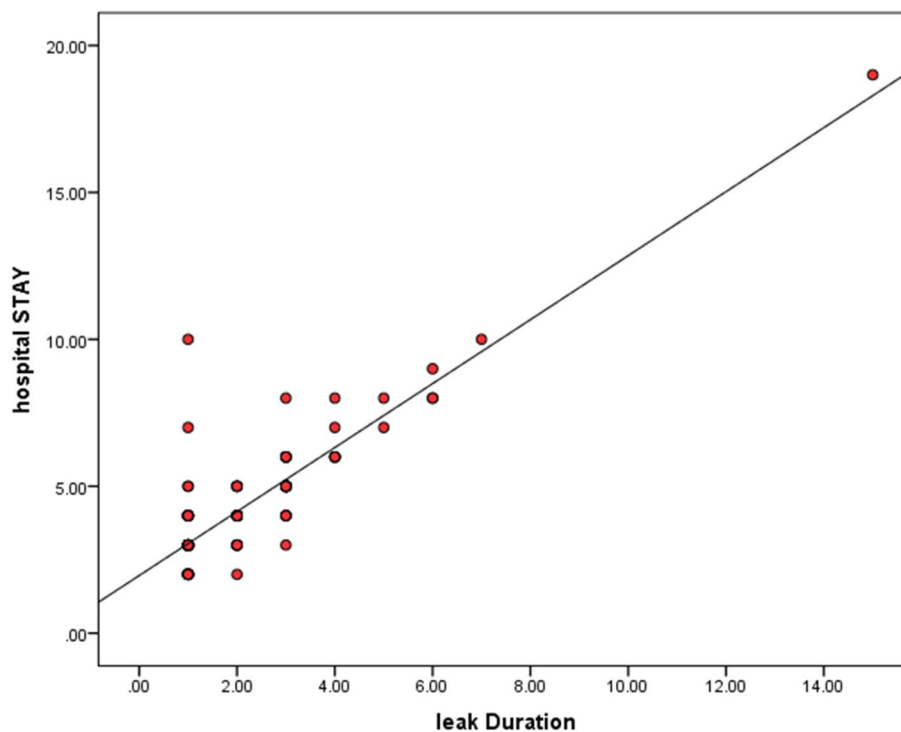


Fig. 3 Relationship among postoperative leak duration & hospital stay duration

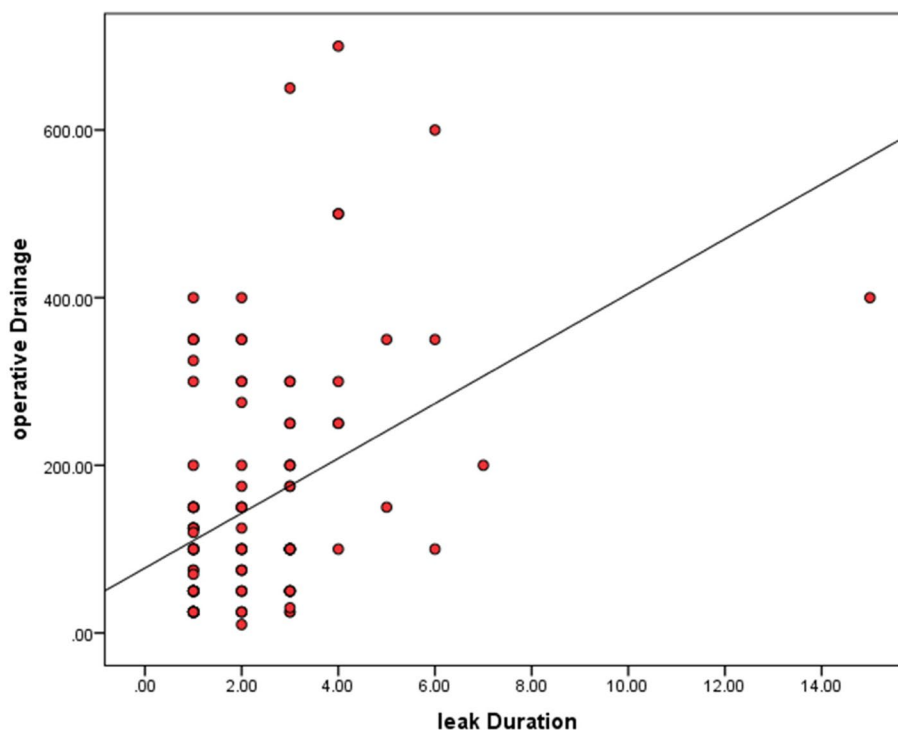


Fig. 4 Relationship among postoperative leak duration & operative drainage

Discussion

In this study investigating 120 patients with pneumothorax who required surgery and divided into two groups according to type of thoracoscopic surgery they had, there is no important variation in patient characteristics among VATS bullae ligation and VATS bullectomy using staplers.

There is only one previous research which investigate results of VATS ligation of bullae by silk ligature in comparison with using staplers in VATS bullectomy. by Mo et al. [7] as they used hand ligation of blebs under biportal video-assisted thoracoscopic surgery or bullectomy with staplers below triportal video-assisted thoracoscopic surgery on sixty six consecutive studied cases with primary spontaneous pneumothorax. There was no statistically important variation among VATS bullae ligation and VATS bullectomy using staplers as regard age, sex, smoking, diagnosis, side of pneumothorax and number of bullae.

In contrary to Mo et al., we included in our study all patients diagnosed with primary and secondary spontaneous pneumothorax and VATS bullectomy was done by uniportal and multiportal VATS.

Our study was in line with Mo, 2019 [8] 1) recurrent ipsilateral pneumothorax; 2) prolonged air leak over four days in 1st episode of pneumothorax; 3) visible large bullae >ten mm in diameter on chest CT; 4) bilateral

pneumothorax in 1st episode; & 5) presence of contralateral pneumothorax.

In addition, Ansheng et al. [6] report 84 cases of spontaneous pneumothorax treated by thoracoscopic surgery, including 54 cases with biportal thoracoscopic bulla ligation (experiment group), and 30 cases with triportal thoracoscopic bulla cutting and suture wedge resection. case (control group). There was no variation in clinical effects among 2 groups ($P > 0.05$).

The current study showed that operation duration and intra-operative bleeding are statistically significant higher in VATS bullectomy using staplers than VATS bullae ligation that could be attributed to:—(1) Cartridges of stapler may involve more lung tissue than ligation, which subsequently increase air leak duration. (2) Pleurectomy was done in 26.7% of patients who were operated by staplers in comparison to none of patients operated by ligation and this might affect the amount of bleeding. (3) VATS bullectomy using staplers was done by multiple surgeon at different levels of learning curve. Those three causes may explain increasing in the operative duration, intra-operative bleeding and post-operative drainage in stapling group. VATS wedge resection was performed in 56.7% of patients who were operated by stapler in comparison to none of patients operated by ligation.

In contrary to our results the research of Mo et al. [7] as they described that there was no variation in operating time among the two groups which might be attributed to the fact that all patients were operated on the same institute with the same surgical team.

In the study of Addas et al. [8] Bullectomy & pleurectomy were performed on all studied cases. Bullectomy was done on all studied cases, even those who did not have blebs or bullae; wedge resection of upper lobe apex was also done. There were no unpleasant occurrences. Blebs & bullae were discovered in 112 (83.5percent) of studied cases. Average blood loss was less than one hundred mL in 129 (ninety six percent) of cases which was similar to current study as patients in both groups did not exceed 100 ml intraoperatively (26.500 ± 12.048 in ligation group and 80.083 ± 31.075 in stapler group). All cases in the Addas et al. series had satisfactory air leak testing prior to closure.

Furthermore, Chen et al. [9] mean operative duration for non-simultaneous & simultaneous processes was (45.6 ± 18.3) min (range twenty five ~ ninety six min) & (120.6 ± 28.7) min (range 84 ~ 166 min).

In the study in our hands, air leak duration and postoperative drainage are statistically significant higher in VATS bullectomy using staplers than VATS bullae ligation. Hospital stay duration is statistically significant higher in stapler group than ligation group.

However, research of Mo et al. [7] there was no difference among both studied group as regard chest tube drainage (mL), Postoperative drainage duration, air leak duration. They discovered significant decrease in postoperative costs for hand ligation of blebs when compared to method of bullectomy with stapler.

In the study of Mo, [8] mean time of postoperative hospital stay was 4.65 ± 1.47 days.

According to Puri et al. [10] Mean duration to removal of chest tubes was four days (two-twelve days). Mean hospital stay was 3.83 days (two-nine days).

Furthermore, Ansheng et al. [6] revealed that the hospitalization expenses of experimental group were lower than those of control group [(16 747.30 \pm 2 586.41) yuan vs (21 088.54 \pm 6 005.68) yuan, $P < 0.05$] and was in agreement with our study which revealed that cost of stay are statistically significant higher in VATS bullectomy using staplers than ligation group with a mean of 962.5 ± 326.2 L. E in ligation group compared to 1688.33 ± 980.8 L.E in stapler group. Also, total cost are statistically significant higher in VATS bullectomy using staplers than VATS bullae ligation with a mean of 4498.17 ± 338.4 L.E in ligation group compared to $12,106.5 \pm 1572.5$ L.E in stapler group.

Our outcomes showed that complications are statistically significant higher in VATS bullectomy using

staplers than VATS bullae ligation. The cost and postoperative leak duration has statistically significant positive correlation with operative bleeding, operative air leakage, and hospital stay duration.

Our outcomes were reinforced by research of Mo et al. [7] because they showed no variation in recurrence among 2 groups there was no need for open surgery in either group, & there were no problems. In Mo et al. series, follow-up period ranged from twenty seven to 1,060 days, & 6 studied cases experienced recurrence, but we follow up patients for 90 days and we report less than 2% recurrence rate.

Also, Puri et al. [10] revealed that there were no postoperative complications. Average duration of follow-up was 25.05 months (six-sixty months). The overall problem rate was 3.6percent ($n =$ four) with recurrence occurring in 2.7percent ($n =$ three) of cases.

Also our study did not include postoperative follow up CT scans, we report less recurrence rate compare to Choi et al. who conduct a metanalysis [11] twenty one (24.7percent) of eighty five CT scans tested were diagnosed with recurrent pneumothorax, & sixty new bullae were discovered. In total, thirty nine new bullae were discovered in staple line, thirty eight at other locations far from staplers, & seventeen in both stapling & non-stapling areas at same time. Following VATS, group with new bullae in staple line had significantly higher recurrence rate than group without new bullae in staple line ($P = 0.000$, log-rank test).

Our method required no expensive endoscopic supplies & only 2 incisions. Thereby, method may have following potential benefits: (I) lowering hospital costs; (II) ligation is simple & reliable technique of tying knots; (III) technique is simple to master; (V) lower rate of recurrence in short term results; & (VI) bleb ligation may be faster & more effective than wedge resection. Method used for biportal thoracoscopic surgery is more limited than endoscopic stapling devices, & potential long-term disadvantages of this method are unknown.

Conclusions

Treatment of spontaneous pneumothorax by thoracoscopic ligation of bullae by silk ligature is comparable to VATS bullectomy using staplers in short-term results and offers less complications and better economic results. Nonetheless, this technique's experience is limited to short-term results. It is critical that additional study affirmed long-term advantages of this method.

Abbreviations

VATS Video-assisted thoracoscopic surgery

CBC	Complete blood count
RFTs	Renal function tests
LFTs	Liver function tests
ICU	Intensive Care Unit

Acknowledgements

We would like to thank the Chinese researchers who helped me in data collection from the Chinese registration system in 2nd affiliated Hospital, Harbin Medical University.

Authors' contributions

Mohamed Osman Omar Hassan: Data collection, data analysis, study design and manuscript writing. Linyou Zhang: Data collection and supervision. Mahmoud Khairy El-Haish: Supervision and manuscript revision. Mohsen Saber Mohamed Ahmed: Supervision and manuscript revision. Hussein Elkhatay: Data collection and help in study design, manuscript writing and revision. The author(s) read and approved the final manuscript.

Funding

No fund.

Availability of data and materials

The data sets used and analyzed in this study are available upon reasonable request.

Declarations

Ethics approval and consent to participate

Research was accepted by Ethics Board of South Valley university (Code:—SVU-MED-CTS012-2–20-2–28).

Consent for publication

This is retrospective study and consent for publication is not available.

Competing interests

None.

Author details

¹Cardiothoracic Surgery Department, Faculty of Medicine, South Valley University, Qena, Egypt. ²Thoracic Surgery Department, 2nd affiliated hospital, Harbin Medical University, Harbin, China. ³Cardiothoracic Surgery Department, Faculty of Medicine, Assiut University, Assiut, Egypt. ⁴Cardiothoracic Surgery Department, Faculty of Medicine, Sohag University, Sohag, Egypt.

Received: 11 October 2022 Accepted: 21 February 2023

Published online: 25 March 2023

References

- Melton L, Hepper N, Offord K (1979) Incidence of spontaneous pneumothorax in Blomstedt County, Minnesota. *Am Rev Respir Dis* 120:1379–1381
- Light R (1993) Management of spontaneous pneumothorax *Rev Respir Dis* 148:245–248
- Ng C, Rocco G, Wong R et al (2014) Uniportal and single-incision video-assisted thoracic surgery: the state of the art. *Interact Cardiovasc Thorac Surg* 19:661–666. <https://doi.org/10.1093/icvts/ivu200>
- Ramzi A, Farid M, Donna E (2016) Is VATS Bullectomy and Pleurectomy an Effective Method for the Management of Spontaneous Pneumothorax. *OJTS* 6(3):25–31.
- Hsin et al (2014) (2014): Cost and effectiveness of video-assisted thoracoscopic surgery clinical stage I non-small cell lung cancer : a population based metanalysis. *J Thorac Dis* 6(12):1690–1696
- Ansheng M, Yuzhong L, Yitong W (2015) Low-cost biportal endoscopic surgery for primary spontaneous pneumothorax. *J Thorac Dis* 7(4):704–710
- Mo A, Luo Y, Yang X et al (2015) Low-cost biportal endoscopic surgery for primary spontaneous pneumothorax. *J Thorac Dis* 7(4):704–710
- Mo A (2019): Low-cost of uniportal thoracoscopic surgery for primary spontaneous pneumothorax. *Respir Med Case Rep*, 28: 100878. doi: <https://doi.org/10.1016/j.rmcr.2019.100878>. PMID: 31341761; PMCID: PMC6630017.
- Chen Y, Luh S, Hsu K et al (2008) Video-assisted thoracoscopic surgery (VATS) for bilateral primary spontaneous pneumothorax. *J Zhejiang Univ Sci B* 9(4):335–340
- Puri H, Asaf B, Pulle M et al (2021) Video-assisted thoracoscopic surgery management of primary spontaneous pneumothorax: Results in 110 consecutive cases. *Lung India: official organ of Indian Chest Society* 38(1):36
- Choi S, Kim D, Suh J et al (2018) New bullae formation in the staple line increases the risk of recurrent pneumothorax following video-assisted thoracoscopic surgery bullectomy for primary spontaneous pneumothorax. *J Thorac Dis* 10(7):4287–4292

Publisher's Note

Springer Nature remains neutral with regard to jurisdictional claims in published maps and institutional affiliations.

Submit your manuscript to a SpringerOpen[®] journal and benefit from:

- Convenient online submission
- Rigorous peer review
- Open access: articles freely available online
- High visibility within the field
- Retaining the copyright to your article

Submit your next manuscript at ► [springeropen.com](https://www.springeropen.com)