


CASE REPORT

Open Access



Surgical treatment for accidentally discovered pseudoaneurysm of the mitral-aortic intervalvular fibrosa with bicuspid aortic valve, ascending aortic aneurysm, and myocardial ischemia: a case report

Kentaro Kiryu^{*} , Gembu Yamaura, Itaru Igarashi, Takayuki Kadohama, Fuminobu Tanaka, Daichi Takagi, Yoshinori Itagaki, Takeshi Arai, Takuya Wada and Hiroshi Yamamoto

Abstract

Background: Pseudoaneurysm of the mitral-aortic intervalvular fibrosa (P-MAIVF) is a rare complication of infective endocarditis and aortic valve replacement. Ruptured P-MAIVF and angina due to compression of the coronary arteries are severe complications of this condition.

Case presentation: We report a case of P-MAIVF that was diagnosed accidentally during a routine checkup. The patient was asymptomatic; however, she had a systolic murmur. She had a history of infective endocarditis, which was treated conservatively without open-heart surgery. In addition, she was diagnosed with aortic valve stenosis, aortic valve regurgitation, bicuspid aortic valve, right coronary artery stenosis, and an ascending aortic aneurysm. She was treated with surgery, which involved patch closure of P-MAIVF with aortic valve replacement, coronary artery bypass grafting, and ascending aorta replacement. After the operation, echocardiography showed no leakage from the P-MAIVF.

Conclusions: It is necessary to have knowledge of P-MAIVF. Following up cases of infective endocarditis and post-aortic valve replacement using echocardiography is important for both, diagnosing P-MAIVF and preventing serious complications such as rupture and angina.

Keywords: Pseudoaneurysm of the mitral-aortic intervalvular fibrosa, Infective endocarditis, Bicuspid aortic valve, Aortic valve regurgitation, Case report

Background

Pseudoaneurysm of the mitral-aortic intervalvular fibrosa (P-MAIVF) is a rare complication of infective endocarditis (IE) and aortic valve replacement (AVR). We experienced a case of P-MAIVF that was diagnosed accidentally; the patient was asymptomatic. Some studies have reviewed clinical cases of P-MAIVF [1–4], and the

association between P-MAIVF and IE, AVR, and bicuspid aortic valves (BAVs). Although our case had no clinical symptoms, a large P-MAIVF could rupture and compress the coronary artery, possibly resulting in fatal complications. Therefore, its diagnosis and follow-up using echocardiography after IE or AVR are important, essentially after treatment.

* Correspondence: k.kiryu83@gmail.com

Department of Cardiovascular Surgery, Akita University Graduate School of Medicine, Hondo 1-1-1, Akita 010-8543, Japan



© The Author(s). 2021 **Open Access** This article is licensed under a Creative Commons Attribution 4.0 International License, which permits use, sharing, adaptation, distribution and reproduction in any medium or format, as long as you give appropriate credit to the original author(s) and the source, provide a link to the Creative Commons licence, and indicate if changes were made. The images or other third party material in this article are included in the article's Creative Commons licence, unless indicated otherwise in a credit line to the material. If material is not included in the article's Creative Commons licence and your intended use is not permitted by statutory regulation or exceeds the permitted use, you will need to obtain permission directly from the copyright holder. To view a copy of this licence, visit <http://creativecommons.org/licenses/by/4.0/>.

Case presentation

A 60-year-old woman had a history of IE when she was 19 years old, and was treated with penicillin, without open-heart surgery. She underwent routine medical examinations without echocardiography. A systolic murmur was noted from the age of 57 years; however, as she was asymptomatic, a detailed examination was not performed at that time. At 60 years of age, during a routine checkup, chest radiography showed no pulmonary congestion, and the cardiothoracic ratio was 48.3%. Echocardiography revealed severe aortic valve stenosis (AS) and aortic valve regurgitation (AR) (degree I) with a BAV; the left ventricular end-diastolic diameter was 41.1 mm, left ventricular end-systolic diameter was 26.9 mm, and ejection fraction 64%. There was no focal asynergy; the aortic valve area was 0.86 cm², and the transaortic valve flow was 4.63 m/s, with 86 mmHg maximum pressure gradient and 49 mmHg mean pressure gradient. A cavity was found in the mitral-aortic fibrosa (Fig. 1A); the size was 13 mm and it expanded during systoles. P-MAIVF was first identified at this point. Computed tomography (CT) showed an ascending aortic aneurysm measuring 49 mm in diameter. Coronary CT showed right coronary artery origin abnormality, right coronary artery orifice stenosis (Fig. 2), and a cavity in the MAIVF (Fig. 1B). Initially, we were unaware of the cavity in the MAIVF; however, after searching the literature on the subject, we diagnosed the cavity as P-MAIVF. Hence, we planned the following surgeries: AVR, ascending aortic replacement, coronary artery bypass grafting (CABG), and P-MAIVF repair with patch closure.

We performed the operation under general anesthesia. We inserted an arterial line from the left radial artery and central venous and Swan–Ganz catheters from the right jugular vein. Cardiopulmonary bypass was established with bicaval drainage and right axillary artery perfusion with a connecting 9-mm graft (J Graft, Japan

Lifeline Co, Ltd, Tokyo, Japan). This was needed as she had an enlarged aortic diameter of 38 mm near the brachiocephalic artery; right axillary artery perfusion had to be established in preparation for possible circulatory arrest during the distal anastomosis procedure on the ascending aorta. Fortunately, she underwent the distal anastomosis procedure without circulatory arrest. A left ventricle vent tube was inserted from the right upper pulmonary vein. Moreover, we performed antegrade infusion for cardioplegia from the ascending aorta and retrograde infusion from the coronary sinus, inserting the cannula from the right atrial appendage. We harvested the right great saphenous vein from the right thigh for the right coronary bypass. After aortic cross clamping, we achieved cardiac arrest by injection, cardioplegia by antegrade, retrograde, and both, 1/3 each. We collected the great saphenous vein from the left thigh in preparation for CABG.

First, we resected the ascending aorta, observed the aortic valve, and found the BAV. Some perforations and old abscess scars were observed at the annulus of the aortic valve, indicating old IE of the aortic valve. The orifice of the right coronary artery was narrow; we ligated the origin of the right coronary artery and resected the cusps of the aortic valve. We then identified the cavity in the MAIVF, the entry measured approximately 13 mm; the entry was closed using a bovine pericardium patch. A 21-mm mechanical valve prosthesis [Regent (Abbott Inc., St. Paul, MN, USA)] was then sutured into the aortic root at the supra-annular position. Further, we anastomosed a distal bypass for the right coronary artery using the great saphenous vein. The ascending aortic aneurysm was replaced using a 28-mm straight graft (J Graft, Japan Lifeline Co, Ltd, Tokyo, Japan). Finally, we anastomosed the great saphenous vein and graft using the proximal aorto-coronary bypass. We released the aortic cross clamping and weaned off the

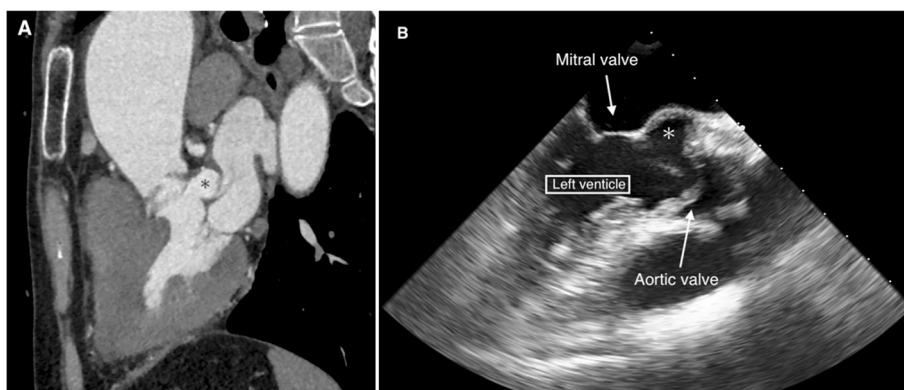


Fig. 1 Preoperative computed tomography and echocardiography. Preoperative computed tomography (A) showing the cavity (asterisk) at the left ventricle outflow tract between the noncoronary cusp of the aortic valve and anterior leaflet of the mitral valve. Preoperative echocardiography (B) also showing the cavity (asterisk) at the same position. This was a pseudoaneurysm of the mitral-aortic intervalvular fibrosa

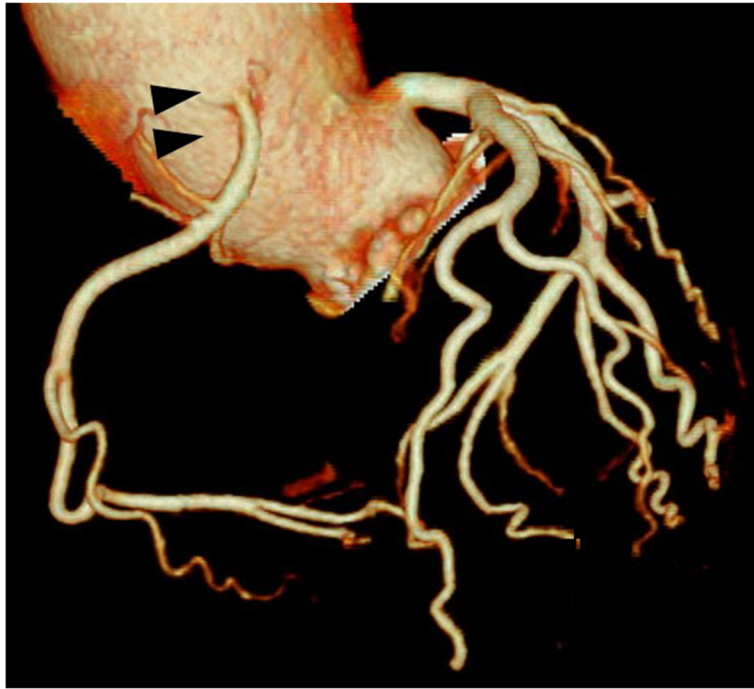


Fig. 2 Preoperative evaluation of the coronary artery by computed tomography. The right coronary artery has high-take-off from the aorta and stenosis noted at its origin (arrows)

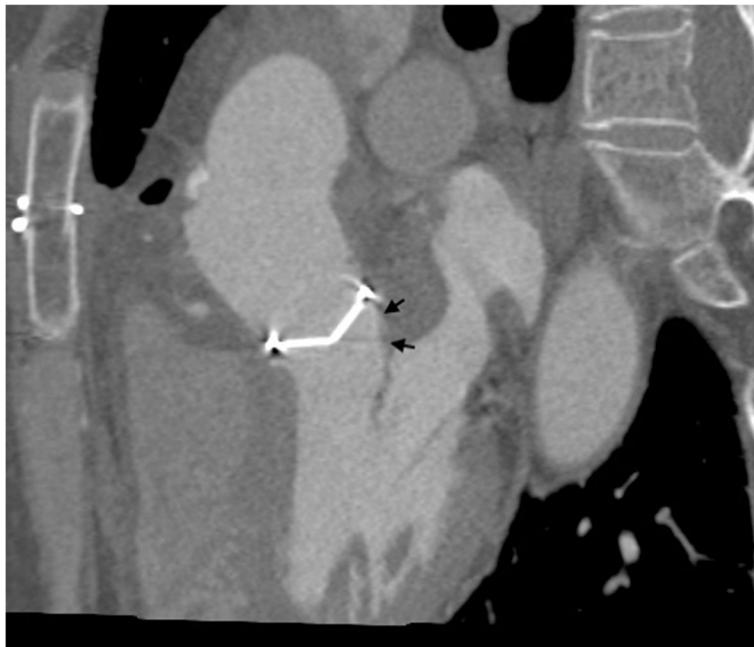


Fig. 3 Post-operative computed tomography. The closed entry (arrows) of the pseudoaneurysm of the mitral-aortic intervalvular fibrosa is seen

cardiopulmonary bypass. After the operation, she was moved to the intensive care unit under general anesthesia and was intubated. On post-operative day (POD) 1, she was extubated after operative echocardiography showed no leakage from the P-MAIVF (Fig. 3). Her condition was stable and she was discharged on POD 20.

Conclusions

P-MAIVF is a rare complication of IE and AVR; clinical descriptions of this complication have been reported in the literature. Abraham et al. [5] described them as “annular subvalvular aneurysms” and later Chesler et al. also described them similarly [6]. In 1967, Layman and January [7] identified “annular subvalvular aneurysms” as P-MAIVF. Moreover, Sahan et al. [2] reviewed 166 cases of P-MAIVF. Most of these patients were in their 30s, and IE and AVR were frequently associated causal factors [1, 8]. Additionally, AR and BAV were described as other causal factors. Chandrakumar et al. [9] reported P-MAIVF without valvulitis as a rare case. Recently, Spampinato et al. [10] reported P-MAIVF after minimally invasive mitral valve repair. MAIVF is a fibrous structure between the aortic and mitral valves, where the anterior mitral leaflet becomes continuous with the noncoronary cusp of the aortic valve. Sudhakar et al. [1] showed that the relative avascular nature of MAIVF makes it prone to infection and injury, resulting in pseudoaneurysm formation. The clinical presentations of P-MAIVF are signs of infection (39%), congestive heart failure (16%), chest pain (10%), cerebrovascular accidents (12%), sudden death (1%), and the absence of symptoms (9%). Almost all patients exhibited some symptoms [1, 4]. Some P-MAIVFs are simple pseudoaneurysms while others are linked to the left atrium or Valsalva sinus. P-MAIVF is occasionally associated with severe complications such as rupture and angina by compression of the coronary artery [1–4]. In a review, other authors had recommended surgical repair for P-MAIVF with or without symptoms to prevent rupture of P-MAIVF [2, 4]. However, some authors reported [11, 12] the use of conservative care for P-MAIVF. The present case was asymptomatic and had other heart diseases; however, we had decided on surgical intervention for P-MAIVF. Conservative care with careful follow-up could have been selected if he would have only had P-MAIVF. Her other heart and aortic lesions (AS, AR, BAV, ascending aorta aneurysm, and stenosis of the right coronary artery) needed open surgery; entry patch closure for P-MAIVF was therefore performed in the same session.

Transesophageal echocardiography is useful in the diagnosis of P-MAIVF [1, 7], while contrast-enhanced CT and magnetic resonance imaging are useful for morphological evaluation. Surgical treatments are generally

recommended to prevent further enlargement of P-MAIVF and its complications. Thus, patch closure of P-MAIVF entry is a common procedure; however, depending on the morphology of P-MAIVF, other procedures, such as the Bentall operation and resection of the pseudoaneurysm, may be selected. Valero et al. [13] reported percutaneous closure of P-MAIVF using the Amplatzer® Muscular VSD Occluder device. Boi et al. reported that they performed transcatheter aortic valve implantation for AS and P-MAIVF [14].

IE is a risk factor of P-MAIVF. Xie et al. [4] reviewed the causative organisms of IE; the causative organisms include *Staphylococcus aureus*, different subtypes of streptococci, tubercle bacillus, enterococcus, *Brucella suis*, *Paecilomyces ilacinus*, *Monilia albicans*, and *Bacillus* spp. The patient described here had IE approximately 30 years previously, and the details were unknown.

In our case, the patient was asymptomatic; her P-MAIVF was small (the diameter was approximately 13 mm) and was considered to be related to the previous IE and BAV. She was diagnosed with AS, AR, BAV, right coronary artery stenosis, and ascending aortic aneurysm and needed open-heart surgery. Thus, we decided to perform patch closure of P-MAIVF. In cases where P-MAIVF is recognized accidentally and other heart diseases are involved, it is necessary to include surgical treatment for P-MAIVF with other open-heart procedures. P-MAIVF is rare and only a few cases are encountered in daily practice. However, the diagnosis of P-MAIVF is particularly important, as it may lead to severe complications such as rupture or angina with enlargement. It is important to have knowledge of an existing P-MAIVF, and echocardiography-based follow-up for IE and AVR cases is therefore essential. We hope that this case report will be more widely read and its recommendations recognized.

Abbreviations

P-MAIVF: Pseudoaneurysm of the mitral-aortic intervalvular fibrosa; IE: Infective endocarditis; AVR: Aortic valve replacement; BAV: Bicuspid aortic valve; AS: Aortic valve stenosis; AR: Aortic valve regurgitation; CABG: Coronary artery bypass grafting; CT: Computed tomography; POD: Post-operative day

Acknowledgements

Not applicable.

Authors' contributions

Writing: KK; illustration: II; review: GY, KT, FT, DT, and HY; summary of patient data: YI, TA, and TW. All authors have read and approved the final manuscript.

Authors' information

KK, MD; GY, MD, PhD; II, MD; TK, MD, PhD; FT, MD; DT, MD, PhD; AT, MD; TW, MD, and HY, MD, PhD, Professor.

Funding

Not applicable.

Availability of data and materials

Not applicable.

Declarations**Ethics approval and consent to participate**

The Akita University Ethics Committee does not require application for approval of observational research for anonymized studies. However, informed consent was obtained from the patient.

Consent for publication

Written informed consent was obtained from the patient for the publication of this case report and accompanying images.

Competing interests

The authors declare that they have no competing interests.

Received: 13 April 2021 Accepted: 31 May 2021

Published online: 08 June 2021

References

1. Sudhakar S, Sewani A, Agrawal M, Uretsky BF (2010) Pseudoaneurysm of the mitral-aortic intervalvular fibrosa (MAIVF): a comprehensive review. *J Am Soc Echocardiogr* 23(10):1009–1018. <https://doi.org/10.1016/j.echo.2010.07.015>
2. Sahan E, Gul M, Sahan S, Sokmen E, Guray YA et al (2015) Pseudoaneurysm of the mitral-aortic intervalvular fibrosa. *Herz* 40(S2):182–189. <https://doi.org/10.1007/s00059-014-4185-z>
3. Varga A, Tilea I, Tatar CM, Lancu DG, Jiga MA et al (2021) Native aortic valve endocarditis complicated by splenic infarction and giant mitral-aortic intervalvular fibrosa pseudoaneurysm—a case report and brief review of the literature. *Diagnostics* 11(251):1–8
4. Xie M, Li Y, Cheng TO, Wang X, Lu Q et al (2013) Pseudoaneurysm of the mitral-aortic intervalvular fibrosa. *Int J Cardiol* 166(1):2–7. <https://doi.org/10.1016/j.ijcard.2012.03.004>
5. Abrahams DG, Barton CJ, Cockshott WP, Edington GM, Weaver EJM (1962) Annular subvalvular left ventricular aneurysms. *QJM* 123:345–368
6. Chesler E, Kornis ME, Porter GE, Reyes CN, Edwards JE (1968) False aneurysm of the left ventricle secondary to bacterial endocarditis with perforation of the mitral-aortic intervalvular fibrosa. *Circulation* 37(4):518–523. <https://doi.org/10.1161/01.CIR.37.4.518>
7. Layman TE, January LE (1967) Micotic left ventricular aneurysm involving the fibrous atrioventricular body. *Am J Cardiol* 20(3):423–427. [https://doi.org/10.1016/0002-9149\(67\)90066-5](https://doi.org/10.1016/0002-9149(67)90066-5)
8. Takamiya Y, Miura S, Sako H, Shirai K, Morishige N, Tashiro T et al (2007) Pseudoaneurysm of the mitral-aortic intervalvular fibrosa following infective endocarditis in a patient with acute heart failure: a case report. *J Cardiol* 49(6):353–356
9. Chandrakumar H, Chowdhury YS, Elamir B, Puskooor A, Shetty M et al (2020) Pseudoaneurysm of the mitral-aortic fibrosa in the absence of valvulitis. *Am J Med Case Rep* 8(12):478–480. <https://doi.org/10.12691/ajmcr-8-12-12>
10. Spampinato RA, Borger MA, Strottdrees E, Mohr FW (2013) Pseudoaneurysm of the mitral-aortic intervalvular fibrosa as a complication after minimally invasive mitral valve repair. *Interact Cardiovasc Thorac Surg* 16(3):396–398. <https://doi.org/10.1093/icvts/ivs502>
11. Gin A, Hong H, Rosenblatt A, Black M, Rlstow B et al (2011) Pseudoaneurysm of the mitral-aortic intervalvular fibrosa: survival without reoperation. *American Heart Journal* 161:130.e1–130.e5
12. Rosario CDR, Scardigno AD, Deluca G, Capodivento S, Quinto N et al (2017) Conservative treatment of a pseudoaneurysm of the mitral-aortic intervalvular fibrosa: 9 years of follow-up. *G Ital Cardiol (Rome)* 18:525–528
13. Valero SJ, Garcia E, Pinto AG, Delcan JL (2005) Percutaneous closure of pseudoaneurysm of the mitral-aortic intervalvular fibrosa. *Rev Esp Cardiol* 58:1473–1475
14. Boi A, Grau G, Rossi A, Lixi G, Armandi L, Fele GS et al (2020) Mitro-aortic fibrosa pseudoaneurysm and concomitant aortic stenosis: how to kill two birds with a stone. *J Card Surg* 35(9):2414–2417. <https://doi.org/10.1111/jocs.14807>

Publisher's Note

Springer Nature remains neutral with regard to jurisdictional claims in published maps and institutional affiliations.

Submit your manuscript to a SpringerOpen[®] journal and benefit from:

- Convenient online submission
- Rigorous peer review
- Open access: articles freely available online
- High visibility within the field
- Retaining the copyright to your article

Submit your next manuscript at ► [springeropen.com](https://www.springeropen.com)